

Unusually large sialolith of the Wharton's duct :

A case report

Vikas Dhillon¹, Ashok Kumar², Bhawna Sharma³

¹Vikas Dhillon, Senior Resident, Department of Otorhinolaryngology, Kalpana Chawla Government medical college Karnal, Haryana, India

²Ashok Kumar, Associate Professor, Department of Otorhinolaryngology, Kalpana Chawla Government medical college Karnal, Haryana, India

³Bhawna Sharma, Demonstrator, Department of Microbiology, Kalpana Chawla Government medical college Karnal, Haryana, India

Abstract: The estimated frequency of occurrence of sialoliths is 1.2%. They are frequently formed in the submandibular gland. They are commonly less than 10 mm in size and rarely larger than 15 mm. We are presenting here such a rare case of Unusually large sialolith of the Wharton's duct in 50 years female who presented to ENT OPD with complaint of swelling, pain and pus discharge from the left floor of the mouth and enlarged left submandibular gland.

On clinical examination a tender hard mass was palpable along the left Wharton's duct. As a part of evaluation protocol, Neck ultrasound was done which revealed left submandibular duct stone confirmed by a CT Scan. Sialolith was removed trans-orally under local anaesthesia. Sialolith measured 20x6 mm. The patient had smooth recovery with no complication in follow up.

Keywords: Sialolithiasis, Wharton's duct, Submandibular gland

Introduction Sialolithiasis is the most common disease of the salivary glands. Sialolith can form in any of the salivary glands, submandibular gland is the most commonly affected site (80–92%), parotid gland in 6–20% of cases and sublingual and minor salivary glands in 1–2%.[1] Its estimated frequency is 1.2% in the adult population, with a slight male predominance[2]. It is believed that salivary calculi develop as a result of deposition of mineral salts around a nidus of bacteria, mucus, or desquamated cells. Sialoliths are composed of varying ratios of organic and inorganic substances. The chemical composition consists mainly of microcrystalline apatite or whitlockite:apatite is the most prevalent component present throughout the stone, while whitlockite is mainly found in the core [3,4].

Commonly, sialoliths measure from 1 mm to <1 cm in size. Giant

salivary gland stones are defined in literature as those stones measuring over 1.5 cm and have been rarely reported in the medical literature.[5,6]

Case Presentation

A 50 year old female patient came to our department with chief complaint of swelling, pain and pus discharge from the left floor of the mouth and enlarged left submandibular gland from last 3 years. There was history of increase in pain and swelling size after eating food. Presently, her pain was continuous, of pricking type and sharp in nature. There was no history of fever, dysphagia or dental trauma. Extraoral examination revealed a diffuse induration in the left submandibular region with normal overlying skin. The swelling was tender on palpation with a firm consistency. Intraorally, bimanual palpations revealed inflammation and induration along the left

Wharton's duct with the absence of salivary flow from the orifice (Figure 1). Pus discharge was detected from the duct orifice. As a part of evaluation protocol neck ultrasound was done which showed left submandibular duct stone with an associated abscess confirmed by computed tomography (CT) scan [Figure 2]. Findings on blood and serum biochemistry were within normal

limits. Medical management was started by intravenous antibiotic for 3 days, followed by left submandibular intraoral stone extraction with marsupialization of the duct under local anesthesia. The calculus was dissected free. The sialoliths was about 2 cm [Figure 2]. The patient had smooth recovery with no complications in follow-up.

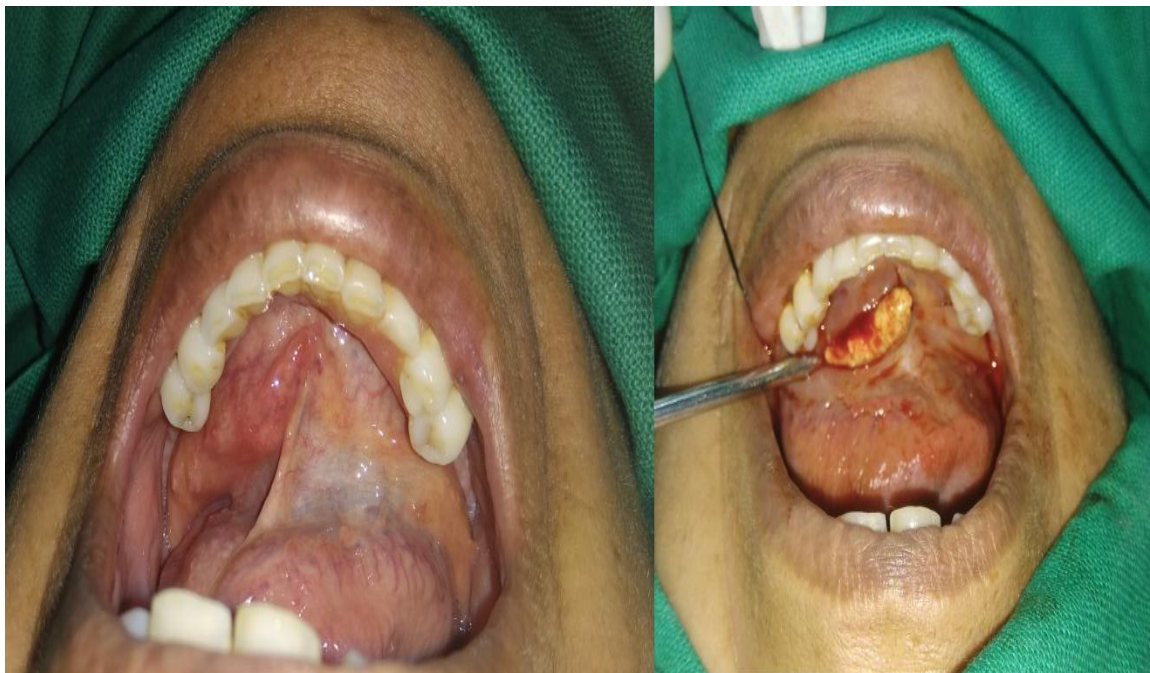

FIGURE 1: Intraoral view showing elevated mass in left side floor of mouth and via trans oral approach sialolith was delivered.

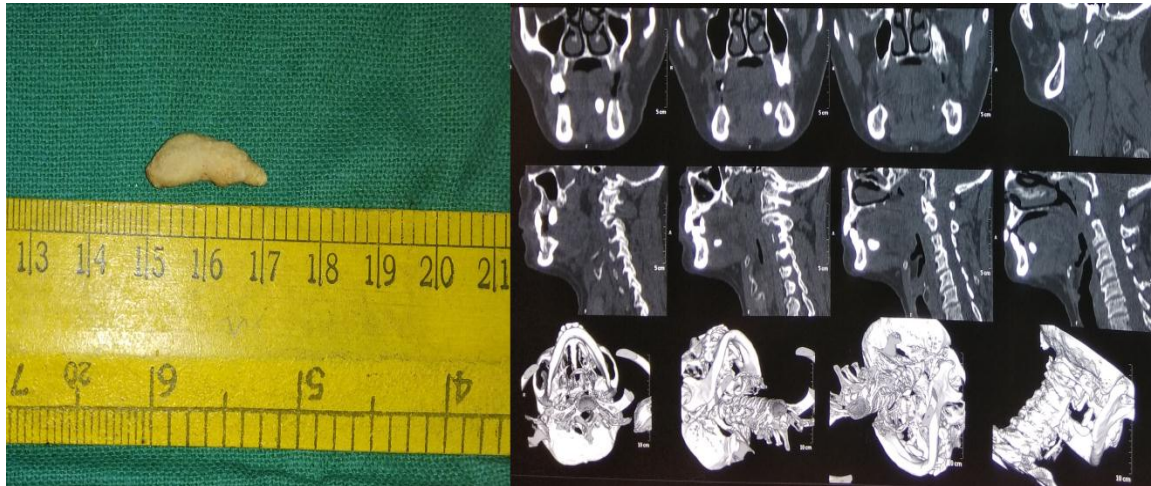


FIGURE 2: Sialolith specimen dimension 20 x 6 mm and CT Scan Head and Neck without contrast shows hyperdense mass seen in distal end of left submandibular duct beyond the substance of submandibular gland.

Discussion Sialoliths commonly measure between 5 and 10 mm in size. Salivary calculi are mainly made up of calcium phosphate with small amounts of carbonates in the form of hydroxyapatite. Magnesium, potassium, and ammonia are components of sialoliths too [7]. Sialolithiasis typically causes pain and swelling of the involved salivary gland by obstructing the post-prandial surge of salivary secretion. Usually, an intraductal sialolithiasis is more severe than an intraglandular one

as the stasis of the salivary flow is more accentuated [8]. Ultrasonography is one of the standard modalities used to diagnosis submandibular stone. On the other hand, 80.0% of long-standing giant submandibular stones are easily seen as most of them were calcified with time and became radiopaque on standard X-ray films. Only one-fifth of the submandibular stones will be missed radiologically on plain X-rays and mostly found with

small stones.[9] The ultrasonography in addition of being an operator-dependent, it does not provide the surgeon with clear and direct anatomic localization of the stone.[10] Although CT scan can pick up both small and large stones depending on the thickness of the cuts, accurate stones localization is lacking. Sialography conventionally has been considered the gold diagnostic standard and provides a good image of the ductal system.[11] The treatment objective for sialoliths is the restoration of normal salivary secretion. We agree with Rai and Burman that a sialolith should be removed in a minimally invasive manner, via transoral sialolithotomy, to avoid morbidity associated with sialadenectomy.[12] Newer treatment methods are currently available such as extracorporeal short-wave lithotripsy and

interventional sialendoscopy. The newer management options are effective alternatives to conventional surgical excision, especially for smaller stone.[13]

Conclusion

Large size submandibular gland stone are rare. There are various methods available for the management of salivary stones, depending on the gland affected and stone location. Newer treatment modalities are effective alternatives to conventional surgical excision for smaller sialoliths. However, for large size stones, transoral sialolithotomy remains the mainstay of management.

Conflict of Interest

No financial or conflict of interest

References

1. McKenna JP, Bostock DJ, McMenamin PG. Sialolithiasis. *Am Fam Physician* 1987;36:119-25.

2. Meyers H. Large calculus in submaxillary gland. *Dent Dig* 1942;48:420..
3. Ashby RA. The chemistry of sialoliths: stones and their homes. In: Norman JED, McGurk M, editors. *Color atlas and text of the salivary glands: diseases, disorders, and surgery*. London, England: Mosby Wolfe; 1995.
4. Anneroth G, Eneroth CM, Isacson G. Crystalline structure of salivary calculi: a microradiographic and microdiffractometric study. *J Oral Pathol* 1975;4:266–72.
5. Bodner L. Giant salivary gland calculi: Diagnostic imaging and surgical management. *Oral Surg Oral Med Oral Pathol Oral Radiol Endod* 2002;94:320-3.
6. Soares EC, Costa FW, Pessoa RM, Bezerra TP. Giant salivary calculus of the submandibular gland. *Otolaryngol Head Neck Surg* 2009;140:128-9.
7. Rai M, Burman R. Giant submandibular sialolith of remarkable size in the comma area of Wharton's duct: a case report. *J Oral Maxillofac Surg* 2009;67:1329–32.
8. Carr SJ. Sialolith of unusual size and configuration. Report of a case. *Oral Surg Oral Med Oral Pathol* 1965;20:709–12.
9. Thoma KH, Gorlin RJ, Goldman HM, editors. *Thomas' Oral Pathology*. St. Louis: Mosby; 1970.
10. Paul D, Chauhan SR. Salivary megalith with a sialo-cutaneous and a sialo-oral fistula: A case report. *J Laryngol Otol* 1995;109:767-9.
11. Baurmash HD. Submandibular salivary stones: Current management modalities. *J Oral Maxillofac Surg* 2004;62:369-78.
12. Rai M, Burman R. Giant submandibular sialolith of remarkable size in the comma area of Wharton's duct: a case report. *J*

Oral Maxillofac Surg

2009;67:1329–32.

13. Walvekar RR, Bomeli SR,
Carrau RL, Schaitkin B. Combined
approach technique for the
management of large salivary
stones. Laryngoscope

2009;119:1125-9.