

# Evaluation of Protective Potentials of Moringa Oleifera Leaf Extract on Testes of Adult Male Wistar Rats

<sup>1</sup>Akudu, L. S.; <sup>1</sup>Ezejindu, D. N.; <sup>1</sup>Nnama, T. N.; <sup>2</sup>Ezejindu, C. N.<sup>1</sup>

Department of Anatomy, College of Health Sciences, Nnamdi Azikiwe University, Nnewi Campus, Anambra State, Nigeria.

<sup>2</sup>Department of Microbiology, Abia State University, Uturu, Abia State, Nigeria.

Corresponding Author's Email: [telltheson@gmail.com](mailto:telltheson@gmail.com)

## ABSTRACT

**Background:** *Moringa oleifera* is highly valued plant reported to have various biological activities. Considering the hepatoprotective properties of *Moringa oleifera*, its protective potential was evaluated on the testes of adult male wistar rats.

**Materials and Methods:** Twenty-four healthy male wistar rats weighing between 190kg-230kg were used. They were divided into four groups (A, B, C & D) of six animals each. Group A served as the control and received 0.3ml of distilled water; the experimental groups (B, C & D) received 0.5ml, 0.6ml and 0.7ml of *Moringa oleifera* leaf extract respectively for twenty-one days. A day after the last

administration, the animals were weighed, and anaesthetized using chloroform vapour and dissected. The testes tissues were removed and trimmed down to a size of 3mm x 3mm and fixed in zenkers fluid for histological studies.

**Results:** Histological results revealed non-distortion of the testicular cells of the experimental groups compared with the control.

**Conclusion:** The result of this study suggests that consumption of *Moringa oleifera* leaf extract at low and high doses may not put the testes at risk of adverse histopathological conditions.

## Keywords:

*Moringa oleifera*; Testes; Body weight; Wistar rats; Hepatoprotective

## INTRODUCTION

Interest in medicinal plants as a re-emerging health aid in the maintenance of personal health and well-being has been fuelled by rising costs of prescription drugs, and the bio prospecting of new plant-derived drugs. The testes are the male gonads in animals.

Like the ovaries to which they are homologous, testes are components of both the reproductive system and endocrine system. The primary functions of the testes are to produce sperm (spermatogenesis) and to produce androgens, primarily testosterone. Natural remedies, mainly from traditional plants are found to be both effective & safe alternatives for the treatment of hepatotoxicity. Extracts from plant sources have also been

investigated for hepatoprotective & antioxidant effects<sup>[3,4]</sup>. *Moringa oleifera* is one of the herbal plants with a wide range of medicinal applicability<sup>[5]</sup>. *Moringa oleifera* (*M. oleifera*), also known as *Moringa pterygosperma* Gaertn, is a member of the Moringaceae family of perennial angiosperm plants, which includes 12 other species<sup>[6]</sup>. Native of the sub-Himalayan northern parts of India, it is cultivated throughout tropical and sub-tropical areas of the world, where it is known by various vernacular names<sup>[7]</sup>, with drumstick tree, horseradish tree, and malunggay being the most commonly found in the literature. In our country Nigeria, it is locally known as Zogeli among the Hausa speaking people of Northern Nigeria. The Yoruba of South-west Nigeria call it Ewe ile or Igi iyaanu (because of its many medicinal uses). While the Igbo speaking people of South-east Nigeria call it names as Okwe oyibo, Oku ghara ite, Odudu oyibo, e.t.c.

*Moringa oleifera* is a rapid growing deciduous shrub or small tree of about 13m tall and 35 cm in diameter with an umbrella-shaped open cap<sup>[8]</sup>, thick, soft, corky, deeply fissured bark. Different parts of the tree have been used in the traditional system of medicine. It is revealed that the *M. oleifera* seeds are being used traditionally as an aphrodisiac<sup>[9]</sup>. The seeds are used to exert its protective effect by decreasing liver lipid peroxides, as an antimicrobial agent<sup>[10]</sup>. The leaves of *M. oleifera* are used as purgative, applied as poultice to sores, rubbed on the temples for headaches, used for piles, fevers, sore throat, bronchitis, eye and ear infections, scurvy and catarrh; leaf juice is believed to control glucose levels, applied to reduce glandular swelling<sup>[11,12,13]</sup>. The stem bark is used as abortifacient and antioxidant activity<sup>[14,15]</sup>. The root of *M.*

*oleifera* were shown to possess antilithic, rubefacient, vesicant, carminative, antifertility, anti-inflammatory, stimulant in paralytic afflictions; act as a cardiac/circulatory tonic, used as a laxative, abortifacient, treating rheumatism, inflammations, articular pains, lower back or kidney pain and constipation<sup>[16,12]</sup>. Moreover, it has been used to enhance male sexual functions including libido, improve sperm quality and anti-erectile dysfunction. Thawatchai et al., 2012 demonstrated that rats subjected to *Moringa oleifera* leaves extract could enhance male sexual desire, mounting, intromission numbers and performance<sup>[17]</sup>.

In view of the consumption of *Moringa oleifera* leaf extract for the maintenance of health and well-being and for the enhancement of male fertility, mounting, and intromission, we therefore aimed at investigating the protective potentials of *Moringa oleifera* leaf extract on the testes of adult wistar male rats.

## MATERIALS AND METHOD

### Breeding of Animals

Twenty-four male wistar rats weighing between 190kg-230kg were purchased from the animal house of Anatomy Department University of Calabar, Cross River State, Nigeria. They were bred in the animal house of university of Uyo, Akwa Ibom State, Nigeria. They were allowed for seven days for acclimatization under normal temperature (27°C – 30°C) before their weights were taken. They were fed ad-libitum with water and guinea feed pellets from Agro feed mill Nigeria Ltd.

## Drug Preparation

*Moringa oleifera* leaves were collected from Mbaise in Imo State and was dried in an oven at a temperature of 50°C and crushed using laboratory blender. Extraction was done using ethanol. 250mg of this extract /kg body weight was dissolved in 10mls of distilled water and administered to the animals.

## Experimental Protocols

The twenty-four animals were weighed and allocated into four groups (A, B, C & D) of six animals each. Group A served as the control and administered 0.3ml of distilled water; the experimental groups B, C & D were administered 0.5ml, 0.6ml and 0.7ml of *Moringa oleifera* extract respectively for

twenty-one days. Both the control and experimental groups were scarified using the chloroform inhalation method. Testes tissues were removed, trimmed down and fixed in zenkers fluid for histological studies. The tissues were transferred into an automatic processor where they went through a process of dehydration in ascending grades of alcohol 70%, 80%, 95% and absolute alcohol for two changes each. The tissues were then cleared in xylene and embedded in paraffin wax. Serial sections of 5 micron thick were obtained using a rotary microtome. The tissue sections were deparaffined hydrated and stained using the routine haematoxylin and eosin staining method (H &E). The stained sections were then examined under the light microscope.

## RESULTS

### Morphometric Analysis of Body Weights

**Table 1:**

**Comparison of mean initial and final body weight and weight change in all the groups (A, B, C & D)**

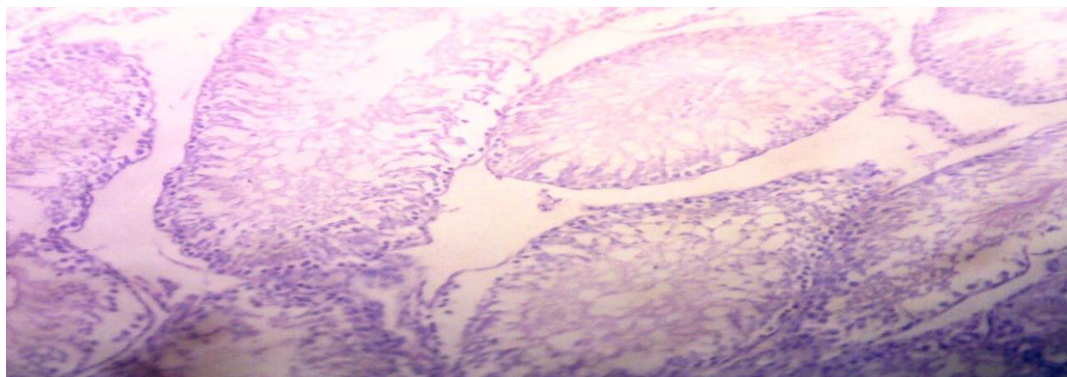
(Mean  $\pm$  SEM given for each measurement)

	GP. A	GP. B	GP. C	GP. D	F-RATIO	PROB. OF SIG
<b>INITIAL BODY WT</b>	198.20 $\pm$ 4.50	206.80 $\pm$ 3.60	219.10 $\pm$ 5.10	226.20 $\pm$ 3.30	66.140	<0.001
<b>FINAL BODY WT</b>	218.00 $\pm$ 4.10	220.30 $\pm$ 5.30	220.30 $\pm$ 5.30	235.40 $\pm$ 5.40	34.220	<0.001
<b>WEIGHT CHANGE</b>	19.80 $\pm$ 2.30	13.50 $\pm$ 4.60	9.40 $\pm$ 2.70	9.20 $\pm$ 4.80	6.340	<0.001

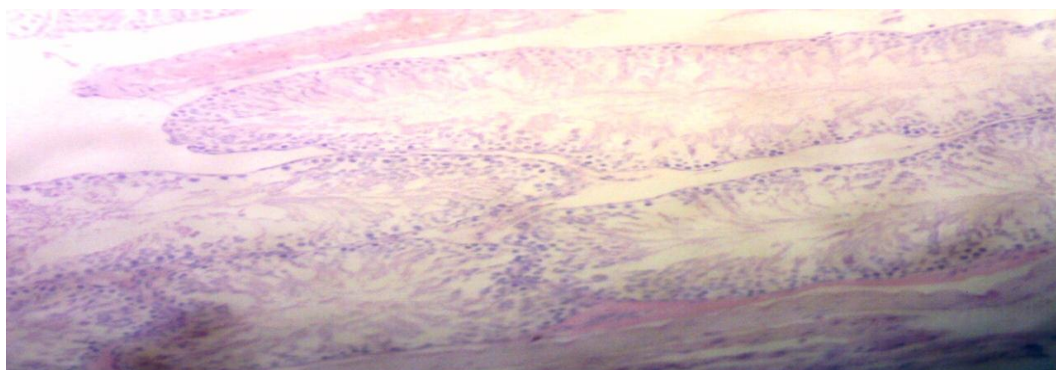
The final body weight for the experimental groups increased significantly ( $P < 0.001$ ) relative to the control (Group A).

### Histopathological Findings

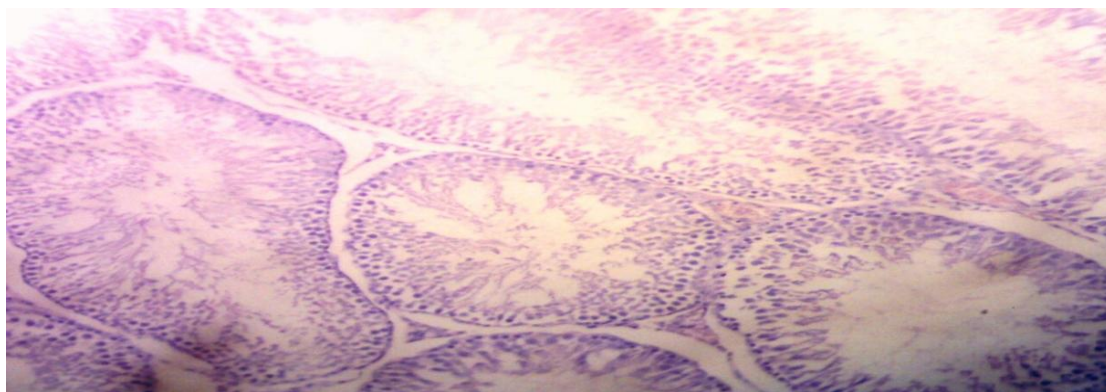
Figure 1, 2, 3 and 4 shows the Histopathological Structure of Testes.



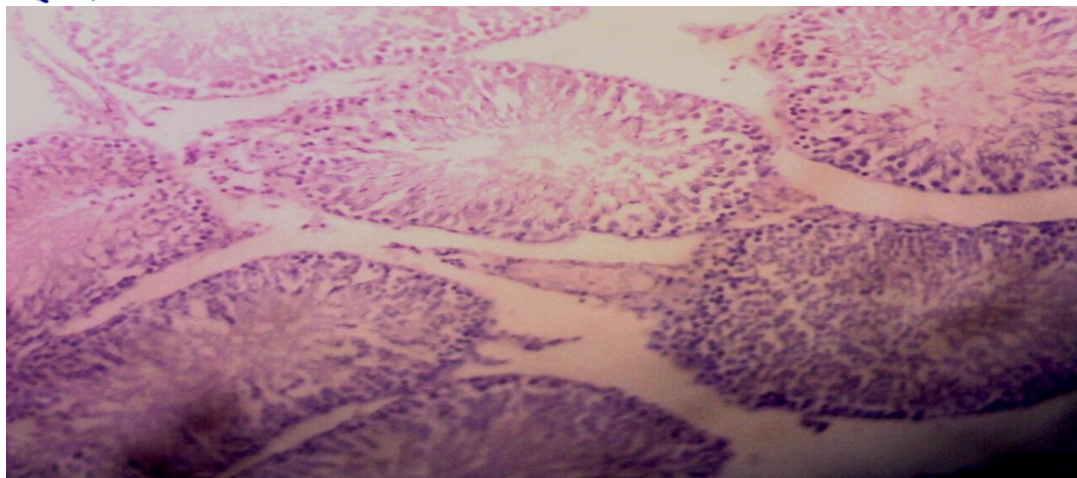
**Figure 1: Group A (Control Group): Showing the Normal Arrangement of Germinal Cells, Sertoli Cells and Leydig Cells. Stained with H&E Technique x200**



**Figure 2: Group B (Group Administered with 0.5ml): Showing Normal Arrangement of Leydig Cells, Sertoli Cells and Germinal Cells with Enhanced Spermatids. Also, No Evidence of Distortion is seen in the Interstitial Tissue. Stained with H&E Technique x200**



**Figure 3: Group C (Group administered with 0.6ml): Showing Normal Arrangement of Sertoli Cells and Leydig Cells. There is no Loss of spermatids and no Necrotic changes in the Interstitial Tissue. Stained with H&E Technique x200**



**Figure 4: Group D (Group Administered with 0.7ml): Showing no Distortion in Normal Histological Structure. There is Non-alteration of the Spermatid Cells and no Necrotic changes both in Seminiferous Tubules and the Interstitial Tissue. Stained with H&E Technique x200**

## DISCUSSION

Medicinal plants have been used by all civilizations as a source of medicines since ancient times. In the recent times, there have been growing interest in exploiting the biological activities of different medicinal herbs, due to their natural origin, cost effectiveness and lesser side effects [18]. Some medicinal plants are extensively used as aphrodisiac to relieve sexual dysfunction, or as fertility enhancing agents. They provide a boost of nutritional value thereby improving sexual performance and libido [19,20].

*Moringa oleifera* is a medicinally important plant, belonging to family Moringaceae. *Moringa oleifera* has great use medicinally both as preventative and treatment. Its bark, sap, roots, leaves, seeds, oil, and flowers are used in traditional medicine in several countries. A folk remedy for stomach complaints, catarrh, cancer [21], gastric ulcers, skin diseases,

lowering blood sugar, increasing bone density, nervous conditions, diabetes, fatigue, increase lactation, hay fever, impotence, edema, cramps, hemorrhoids, headaches, sore gums; to strengthen the eyes and the brain, liver [22].

In the present study, adult male wistar rats treated with different doses of *Moringa oleifera* leaf extract were used. The final body weight of the experimental animals increased significantly relative to control (Group A). The extract of *Moringa oleifera* leaf in this instance provide a boost of nutritional value enhancing growth.

The histopathological results revealed that there were non-distortion of testicular cells observed in the experimental groups treated with different doses of *Moringa oleifera* leaf extract compared with the control (group A). This could be as a result of antitumor and anti-inflammatory properties of *Moringa oleifera*. *Moringa oleifera* contains specific plant pigments with demonstrated powerful

antioxidative ability such as vitamins C, E, A, caffeoylquinic acids, carotenoids - lutein, alpha-carotene and beta carotene, kaempferol, quercetin, rutin <sup>[23,24,25]</sup>.

The result of this research is in conformity with the study done by Stohs and Bagchi, (1995) which showed that pretreatment with *Moringa oleifera* leaf extract shield the testes from a variety of toxic substances <sup>[26]</sup>. Also it corroborates with the study by Godson et al., 2012 which showed that *Moringa oleifera* leaf extract had a protective effect against the toxicity which was evidenced by improvement in sperm parameters of rats treated with chromium and *Moringa oleifera* leaf extract <sup>[27]</sup>. Also, it is in accordance with the studies by Varsha et al., 2013 who stated that the extract was also observed to be devoid of any adverse effects and acute toxicity <sup>[28]</sup>

## CONCLUSION

Our present research clearly revealed that *Moringa oleifera* leaf extract administered in high or low doses has antioxidant and protective properties which prevent distortions of the testes.

## REFERENCES

- 1) Sharma, V., Sharma, A, and Kansal, L. (2010): The Effect of Oral Administration of *Allium sativum* Extracts on Lead Nitrate induced Toxicity in Male Mice. Food Chemistry and Toxicology, 48: 928-936.
- 2) Sierens, J. E., Sneddon, S. F., Collins, F., Millar, M. R. and Saunders, P. T. (2005): Estrogens in Testes Biology. Annals of the New York Academy of Sciences. 1061: 65-76
- 3) Yousef, M. I., Omar, S. A., El-Guendi, M. I. and Abdelmegid, L. A. (2010): Potential Protective Effects of Quercetin and Curcumin on Paracetamol-induced Histological Changes, Oxidative Stress, Impaired Liver and Kidney Functions and Haematotoxicity in Rat. Food Chem. Toxicol., 48, 3246-3261.
- 4) Choi, J. H., Choi, C. Y., Lee, K. J., Hwang, Y. P., Chung, Y. C. and Jeong, H.G. (2009): Hepatoprotective Effects of an Anthocyanin Fraction from Purple-fleshed Sweet Potato against Acetaminophen induced Liver Damage in Mice. J. Med. Food, 12, 320-326.
- 5) Vinodini, N. A., Pratik, K. C., Anwar, A., Suman, V. B. and Sheila, R. P. (2014): Evaluation Of Liver Functions With *Moringa Oleifera* Leaf Extract In Cadmium Induced Adult Wistar Albino Rats. Int. J. Plant and Environ. Sci. vol. 4 no. 3: 103-106
- 6) Olson, M. E. (2002): Combining Data from DNA Sequences and Morphology for a Phylogeny of Moringaceae (Brassicales). Syst. Bot. 27, 55-73
- 7) Ramachandran, C., Peter, K. V. and Gopalakrishnan, P. K. (1980): Drumstick (*Moringa oleifera*): A Multipurpose Indian Vegetable. Econ. Bot. 34, 276-283. [10.1007/BF02858648](https://doi.org/10.1007/BF02858648) [\[Cross Ref\]](#)

- 8) Anjorin, S. T., Ikokoh, P. S. and Okolo, A. (2010): Mineral Composition of *Moringa oleifera* Leaves, Pods and Seeds from Two Regions in Abuja, Nigeria. *International Journal of Agriculture and Biology*. 12(3):1560-9.
- 9) Lalas, S. and Tsaknis, J. (2002): Extraction and Identification of Natural Antioxidants from the Seeds of *Moringa oleifera* Tree variety of Malawi. *J Am Oil Chem Soc.* 79: 677-683.
- 10) Faizi, S., Siddiqui, B. S., Saleem, R., Aftab, K., Shaheen, F. and Gilani, A. H. (1998): Hypotensive Constituents from the Pods of *Moringa oleifera*. *Planta Med.* 64: 225-228.
- 11) Morton, J. F. (1991): The Horseradish Tree, *Moringa pterigosperma* (Moringaceae). A Boon to Arid Lands. *Econ Bot.*, 1991; 45: 318-333.
- 12) Dahot, M. U. (1988): Vitamin Contents of Flowers and Seeds of *Moringa oleifera*. *Pak J Biochem.*, 21: 1-24.
- 13) Makonnen, E., Hunde, A. and Damecha, G. (1997): Hypoglycaemic Effect of *Moringa stenopetala* Aqueous Extract in Rabbits. *Phytother Res.*, 11: 147-148.
- 14) Ghasi, S., Nwobodo, E. and Ofili, J. O. (2000): Hypocholesterolemic Effects of Crude Extract of Leaf of *Moringa oleifera* Lam in High-fat Diet fed Wistar Rats. *J Ethnopharmacol.*, 69: 21-25.
- 15) Nath, D. and Sethi, N. (1992): Commonly used Indian Abortifacient Plants with Special Reference to their Teratologic Effect in Rats. *J Ethnopharmacol.*, 36: 147: 154.
- 16) Padmarao, P., Acharya, B. M. and Dennis, T. J. (1996): Pharmacognostic Study on Stem Bark of *Moringaoleifera* Lam. *Bulletin of Medico-Ethno-Botanical Res.*, 17: 141-151.
- 17) Thawatchai, P., Jintanaporn, W., Sitthichai, I., Supaporn, M. and Wipawee, T. (2012): *Moringa Oleifera* Leaves Extract Attenuates Male Sexual Dysfunction. *American Journal of Neuroscience* 3 (1): 17-24.
- 18) Naik, G. H., Priyadarsini, K. I., Satav, J. G., Banavalikar, M. M., Sohani, D. P., Biyani, M. K. and Mohan, H. (2003): Comparative Antioxidant Activity of Individual Herbal Components used in Ayurvedic Medicine. *Phytochemistry*, 63: 97-104.
- 19) Yakubu, M. T., Akanji, M. A. and Oladiji, A. T. (2007): Male Sexual Dysfunction and Methods used in Assessing Medicinal Plants with Aphrodisiac Potentials. *PHCOG Rev.*, 1(1): 49- 52.
- 20) Sumalatha, K., Saravana, K. A. and Mohana, L. S. (2010): Review of Natural Aphrodisiac Potentials to Treat Sexual Dysfunction. *Int J Pharm Ther.*, 1: 10-18.

- 21) Murakami, A., Kitazono, Y., Jiwajinda, S., Koshimizu, K. and Ohigashi, H. (1998): Niaziminin, A Thiocarbamate from the Leaves of *Moringa oleifera*, holds A Strict Structural Requirement for Inhibition of Tumor Promoter-induced Epstein-Barr virus Activation. *Planta Med.*, 64: 319-323.
- 22) Farooq, A., Sajid, L., Muhammad, A. and Anwarul, H. G. (2007): *Moringa oleifera*: A Food Plant with Multiple Medicinal Uses. *Phytotherapy Research*, 21:17 – 25.
- 23) Ho, C. T. Food Phytochemicals and Cancer Prevention. (1994): ACS Symposium Series 547. American Chemical Assoc., Washington DC. p.132-44.
- 24) Siddhuraju, P. and Becker, K. (2003): Antioxidant Properties of Various Solvent Extracts of Total Phenolic Constituents from Three Different Agroclimatic Origins of Drumstick Tree (*Moringa oleifera*, Lam) Leaves. *J Agric Food Chem.* 51(8):2144-55.
- 25) Aslam, M. F., Anwar, R., Nadeem, U., Rashid, T. G., Kazi, A. and Nadeem, M. (2005): Mineral Composition of *Moringa oleifera* Leaves and Pods from Different Regions of Punjab, Pakistan. *Asian J. Plant Sci* 4:417–21.
- 26) Stohs, S. J. and Bagchi, D. (1995): Oxidative Mechanisms in the Toxicity of Metal-ions. *Free Radiology Biology Med* 18:321-36.
- 27) Godson, G. A., Oluwaseyi, S. O., Chia, L. S., Babatunde, O., Ayomide, J. B. and Emmanuel, O. S. (2012): Ameliorative Effect of *Moringa oleifera* (drumstick) Leaf Extracts on Chromium-Induced Testicular Toxicity in Rat Testes. *World J Life Sci. and Medical Research* 2:20
- 28) Varsha, S. Z., Dinesh, K. D., Vaibhao, G. T. and Shital, R. P. (2013): Effect of Aqueous Extract of *Moringa oleifera* Seed on Sexual Activity of Male Albino Rats. *Biological Forum – An International Journal* 5(1): 129-140